



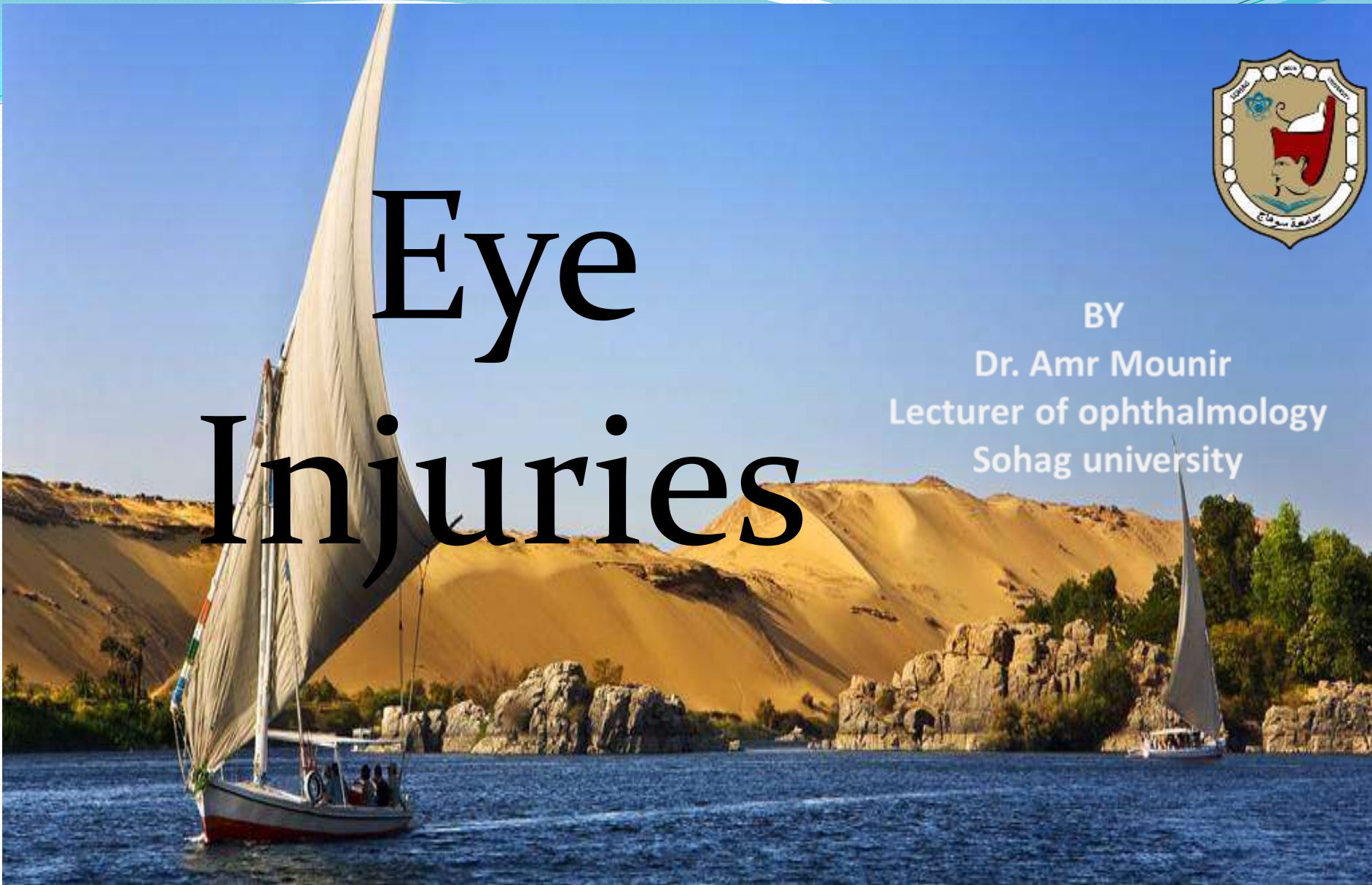
# Eye Injuries

BY

Dr. Amr Mounir

Lecturer of ophthalmology

Sohag university



# Classification:-

Eye Injuries are classified into:

- (1) Blunt injuries.
- (2) Perforating injuries.
- (3) Injuries by foreign bodies.
- (4) Chemical injuries.

# [1] Injuries By Blunt Objects (Contusions)

**Common Objects:** fist, tennis ball, a stick etc...

**Results:** vary from a small corneal abrasion which heals in a few hours, to a rupture globe.

**The effect of injury may appear:**

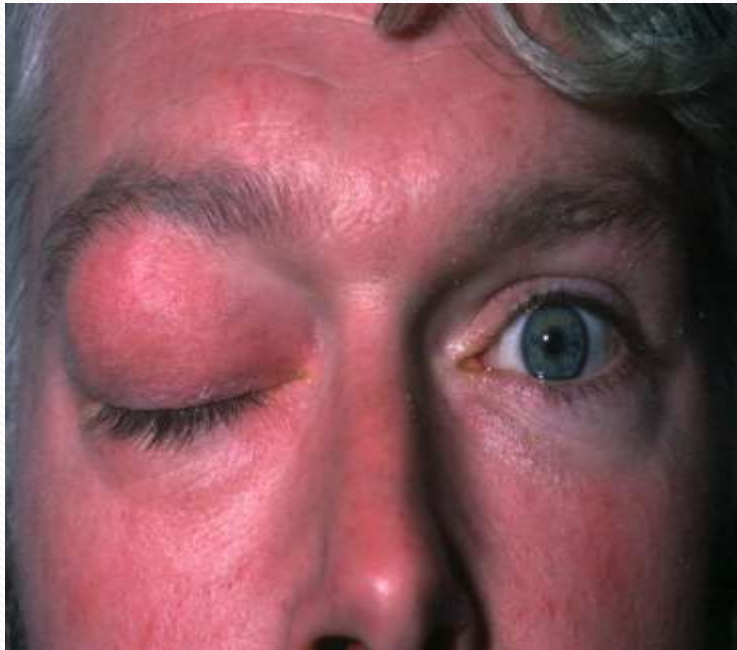- 1) Immediately following the trauma.
- 2) Delayed complications:
  - 1- Macular degeneration. 2- Retinal detachment.
  - 3- Post traumatic irido cyclitis.
  - 4- Post traumatic glaucoma (angle recession glaucoma).

# The results of such injuries may be:

## (1) The Orbit:

- 1) Fracture of bones.
- 2) Traumatic proptosis: due to:
  - 1- retro bulbar haemorrhage.
  - 2- Surgical emphysema.
  - 3- carotid cavernous fistula.
- 3) Pulsating exophthalmos.
- 4) Orbital cellulitis.

Peri orbital sub cutaneous  
emphysema



peri ocular ecchymosis and  
oedema with traumatic  
enophthalmos

